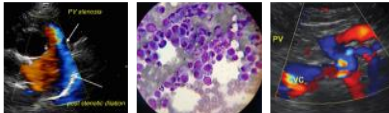


IMAGING PERFORMED BY

IntraPet.com



PATIENT

Ozzy Lasley

SPECIES

Feline

BREED

DSH

SEX

Male Neutered

AGE

5.5.11

WEIGHT

23.4lbs

INTERPRETED BY

Maggie Machen Lamy,
DVM, DACVIM
(Cardiology)

HOSPITAL NAME

Greenbrier Veterinary
Clinic

REFERRING VET

Dr. Dellinger

INVOICE

24313

DATE

5.20.22

PRESENTING CLINICAL SIGNS

History: Grade 2 heart murmur.
-Pertinent abnormal PE/Chem/CBC/UA Results: BNP 1500.
-Current medications: None.
-Sedation used: Not required to complete full diagnostic ultrasound.
-Pertinent previous ultrasound results: No previous.
-STAT: Not requested.
-Imaging performed by: Stephanie Pearce RDCS, RVT.

ECHOCARDIOGRAM FINDINGS

2D, m-mode, color flow and doppler imaging is available. The left ventricular wall is moderately hypertrophied with regions of irregularity. There is a diffusely hyperechoic endocardium consistent with fibrosis and ventricular remodeling. Papillary muscle hypertrophy. The right ventricle is subjectively normal in size and morphology. There is mild left atrial enlargement present. No right atrial enlargement present. Normal RVOT velocity. There is systolic anterior motion (SAM) of the mitral valve present, with an elevated LVOT velocity (dynamic profile). There is mild eccentric mitral regurgitation present secondary to SAM. No other obvious valvular regurgitation is present. There is no pericardial effusion noted. No pleural effusion appreciated.

CARDIAC CHART

FELINE CARDIAC PARAMETERS	BODY WEIGHT (kg)	HR (BPM)	IVSd (cm) <small>(Moise, Pipers)</small>	LVIDd (cm) <small>(Moise, Pipers)</small>	LVWd (cm) <small>(Moise, Pipers)</small>	FS (%)	EF (%)
NORMAL PARAMETER	-----	150-240	3.5-0.55	<2 (mean 1.5)	3.5-0.55	35-67	80-100
PATIENT	10.6	NM	0.75	1.3	0.77	54	88
FELINE CARDIAC PARAMETERS	LA/AO <small>(Boon)</small>	LA/AO HEART BASE (Swe) <small>(Abbott)</small>	LA 2D short axis Base view (cm) <small>(Abbott)</small>		LVOT VEL (m/s)	RVOT VEL (m/s)	E max (m/s)
NORMAL	<1.5	<1.3	<1.2		<1.6	<1.3	<0.9
PATIENT	NM	1.46	1.46		2.5	0.84	NM

Adapted from June Boon, Veterinary Echocardiography, 1998
Abbott J & MacLean H JVIM 2006;20: 111-119, Moise et al. Am J Vet Res 47:1476, 1986. Pipers et al. Am J Vet Res 40:882, 1979.

INTERPRETATION OF THE FINDINGS & FURTHER RECOMMENDATIONS

The diagnosis is hypertrophic obstructive cardiomyopathy. This indicates LV hypertrophy (moderate in this case) with a dynamic LVOT obstruction (SAM) and secondary MR. There is mild left atrial dilation, indicating the risk of spontaneous CHF and/or a thrombotic event, while currently low, may be elevated in the future. A screening BP and T4 are recommended every 6 months, as both can exacerbate disease.

While no medications have been shown to definitively alter long term outcome at this stage of disease, atenolol is often initiated to decrease the outflow obstruction. Given the degree of hypertrophy and mild LA dilation, recommend initiate at this time as below. If there is difficulty medicating at home, an alternative approach would be closely monitoring for progression in the next 6 months.

Anesthetic risk is considered mild, however judicious IV fluid rates are advised to avoid fluid overload. Additionally, drugs that stimulate heart rate should be avoided unless clinically necessary (glycopyrrolate, atropine). Avoid vasodilators as this may worsen the obstruction. A reasonable protocol includes opioid/benzodiazepine premedication, propofol induction, isoflurane maintenance. Risk for complication with steroid use typically follows LA dilation, which in this case is mildly elevated. If needed, monitoring of RR/RE is advised particularly in the initiation phase.

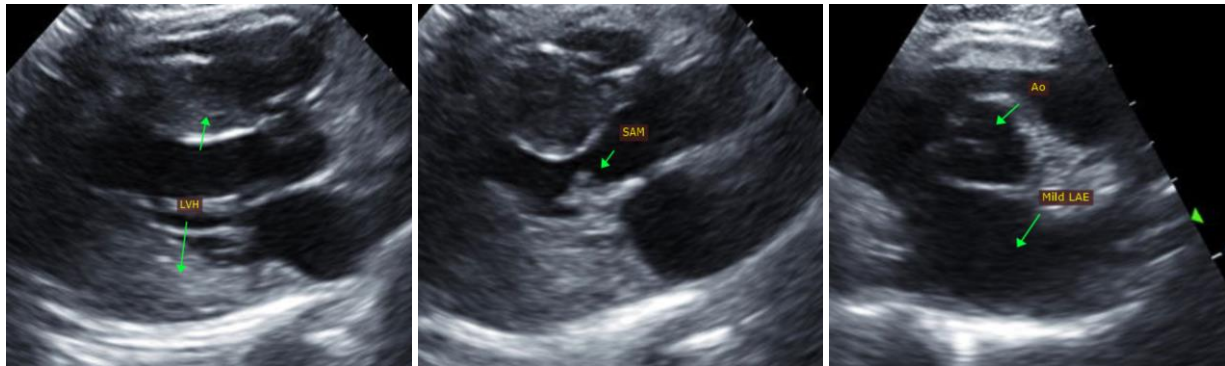
Monitor at home for any respiratory signs or blood clot events (neurologic change, paralysis, etc.) in the future.

PLAN

Screening BP/T4. Administer titrating dose of atenolol: 25mg tablets; Give ¼ tab once daily. Recheck heart rate in 1-2 weeks with target stressed rate of 140-160bpm 12-24 hours post-administration. Increase as needed until target reached.

Recommend recheck echocardiogram in 6 months to assess for progression, sooner if clinical issues arise.

IMAGES



The information and recommendations provided are based on the images presented by the referring veterinarian. No evaluation can be communicated regarding pathology that was not visible in the image/video clips provided.

Thank you for this referral. This report was generated using transcription software, and minor dictation errors may be present. If the clinical or image interpretation does not parallel your findings or if I can be of any further assistance, please contact me.

Maggie Machen Lamy, DVM
Diplomate of the American College of Veterinary Internal Medicine (Cardiology)
info@sonopath.com